



Radiosurgery in Glioblastoma: A Literature Review*

Jose E. Valerio^a ■ Maria P. Fernandez-Gomez^b ■ Noe Santiago^c
■ Andres M. Alvarez-Pinzon^d

Abstract: Managing high-grade gliomas, particularly glioblastoma, remains challenging despite advancements in radiation therapy and surgery. The standard care involves maximal surgical resection, followed by radiotherapy and Temozolomide chemotherapy. Gamma Knife Stereotactic Radiosurgery (GKRS) has emerged as a noninvasive and effective option for treating a range of central nervous system lesions. GKRS offers precise, low-energy radiation delivery to a defined target, inducing tissue destruction while sparing healthy brain tissue. Although, side effects such as radiation necrosis have been noted, GKRS shows promise in treating glioblastoma, even with its infiltrative nature. This review explores the evolving landscape of high-grade glioma management, focusing on the potential of GKRS in improving treatment outcomes.

Keywords: High-Grade Glioma; Glioblastoma; Gamma Knife Stereotactic Radiosurgery

Recibido: 04/11/2023. **Aceptado:** 17/02/2024. **Disponible en línea:** 10/04/2024.

Cómo citar: Valerio, J. E., Fernandez Gomez, M. P., Santiago, N., & Alvarez-Pinzon, A. M. (2024). Radiosurgery in Glioblastoma: A Literature Review. *Revista Med*, 31(2), 71–78. <https://doi.org/10.18359/rmed.7041>

* Literature Review.

- a** Neurosurgery Oncology, Latinoamerica Valerio Foundation, Weston, FL, USA.
Email: jvalerio@jvaleriodm.com
ORCID: <https://orcid.org/0000-0001-7283-5988>
- b** Clinical Research Fellow, Latinoamerica Valerio Foundation, Weston, FL, USA.
Email: mariapaulafg96@gmail.com
ORCID: <https://orcid.org/0000-0002-9506-5282>
- c** Clinical Research Fellow, Latinoamerica Valerio Foundation, Weston, FL, USA.
Email: noe.santiago.rea@hotmail.com
ORCID: <https://orcid.org/0009-0004-7489-5086>
- d** Neurosurgery Oncology, Latinoamerica Valerio Foundation, Weston, FL, USA.
Email: andresmauricioalvarez@gmail.com
ORCID: <https://orcid.org/0000-0003-3488-8020>

Radiocirurgía en glioblastoma: una revisión de la literatura

Resumen: El manejo de gliomas de alto grado, particularmente el glioblastoma, sigue siendo desafiante a pesar de los avances en la terapia de radiación y la cirugía. El cuidado estándar implica una resección quirúrgica máxima, seguida de radioterapia y quimioterapia con Temozolomida. La Radiocirurgía Estereotáctica con Gamma Knife (GKRS) ha surgido como una opción no invasiva y efectiva para tratar una variedad de lesiones del sistema nervioso central. La GKRS ofrece una entrega precisa de radiación de baja energía a un objetivo definido, induciendo la destrucción del tejido mientras preserva el tejido cerebral sano. Aunque se han observado efectos secundarios como la necrosis por radiación, la GKRS muestra promesas en el tratamiento del glioblastoma, incluso con su naturaleza infiltrativa. Esta revisión explora el panorama evolutivo del manejo de gliomas de alto grado, centrándose en el potencial de la GKRS para mejorar los resultados del tratamiento.

Palabras clave: glioma de alto grado; glioblastoma; radiocirurgía estereotáctica con Gamma Knife

Radiocirurgia no glioblastoma: uma revisão da literatura

Resumo: O manejo de gliomas de alto grau, particularmente o glioblastoma, continua sendo um desafio apesar dos avanços na terapia de radiação e cirurgia. O cuidado padrão envolve a ressecção cirúrgica máxima, seguida de radioterapia e quimioterapia com Temozolomida. A Radiocirurgia Estereotáxica com Gamma Knife (GKRS) surgiu como uma opção não invasiva e eficaz para tratar uma variedade de lesões do sistema nervoso central. A GKRS oferece uma entrega precisa de radiação de baixa energia a um alvo definido, induzindo a destruição do tecido enquanto preserva o tecido cerebral saudável. Embora efeitos secundários como necrose por radiação tenham sido observados, a GKRS mostra promessas no tratamento do glioblastoma, mesmo com sua natureza infiltrativa. Esta revisão explora o panorama evolutivo do manejo de gliomas de alto grau, com foco no potencial da GKRS para melhorar os resultados do tratamento.

Palavras-chave: glioma de alto grau; glioblastoma; radiocirurgia estereotáxica com Gamma Knife

Introduction

Gliomas are histologically graded according to the World Health Organization (WHO) on a scale from I to IV, depending on the level of malignancy determined by histopathological criteria. Grades III and IV include high-grade gliomas, which are naturally aggressive and infiltrative (1).

The most prevalent malignant brain tumors are high-grade gliomas, accounting for approximately 70% of the 23,000 malignant brain tumors diagnosed annually in the United States of America (2). They also contribute to approximately 2.5% of cancer-related deaths in individuals aged 15- 34 (3). The annual incidence of high-grade gliomas is 10 per 100,000 people, with a slightly higher incidence reported in males compared to female patients (3).

The most common types of gliomas include astrocytomas, oligodendrogliomas, ependymomas, and mixed gliomas, with glioblastoma multiforme (GBM) being the most aggressive and malignant form among them (3). GBM is the most common primary brain tumor in adults, constituting 15% of all gliomas diagnosed in individuals aged between 45 and 70 (5). The peak age for GBM falls between 50 and 60 years, with a median age at diagnosis of 64 years. However, the incidence of glioblastoma multiforme increases with age (1,2).

According to the Stupp trial, patients older than 60 years demonstrated a median overall survival of 10.9-11.8 months, which can be extended with radiation therapy, offering a 4-month survival advantage compared to supportive care alone (1,2). For patients with glioblastoma, clinical factors influencing prognosis include older age and poor performance status, both associated with shorter survival rates (6). Glioblastoma most commonly occurs in the cerebral hemispheres, with 95% originating in the supratentorial region (3). While brainstem gliomas are common among children, they are rare in adults, accounting for less than 2% of all gliomas. Among adults, three major types of gliomas exist high-grade gliomas, diffuse infiltrating low-grade gliomas, and tectal gliomas. Depending on the type, life expectancy changes (7).

Pathophysiology

During our review, we observed that GBM can be categorized into two primary types based on clinical features. The primary GBMs arise de novo, without evidence of a precursor lesion both clinically and histologically, while secondary GBMs progress slowly from a pre-existing low-grade glioma. In recent studies in the pediatric population, a third type of GBM may be described based on a specific mutation in the histone H3F3 gene. According to the literature, primary GBM characteristic alterations include mutations and amplification of the epidermal growth factor receptor (EGFR) gene, increased expression of mouse double minute 2 (MDM2), deletion of p16, loss of heterozygosity (LOH) on chromosome 10q affecting phosphatase and tensin homolog (PTEN) gene, and mutations in the TERT promoter. In contrast, secondary GBMs exhibit distinct features, including elevated expression of platelet-derived growth factor A and platelet-derived growth factor receptor alpha (PDGFA/PDGFRa), alterations in the retinoblastoma (RB) gene, LOH at 19q, as well as mutations in IDH1/2, TP53, and ATRX(3).

Risk factors

Information about risk factors for primary brain tumors is limited, and there is little consensus regarding their nature and magnitude. Currently, the only confirmed risk factor is exposure to ionizing radiation in high doses (3,4).

However, some studies explore the relationship between various factors and an increased risk of neuroepithelial tissue and meningeal primary brain tumors. These factors include hereditary syndromes (such as tuberous sclerosis, neurofibromatosis types 1 and 2, nevoid basal cell carcinoma syndrome, adenomatous polyposis syndromes, Li-Fraumeni cancer family syndrome), constitutive polymorphisms, Lymphocyte mutagen sensitivity, a history of brain tumors in family records, prior cancers, allergies, head trauma, epilepsy, seizures or convulsions, certain drugs and medications, psychoactive substances, tobacco smoke exposures, some hair dyes and sprays, certain occupations,

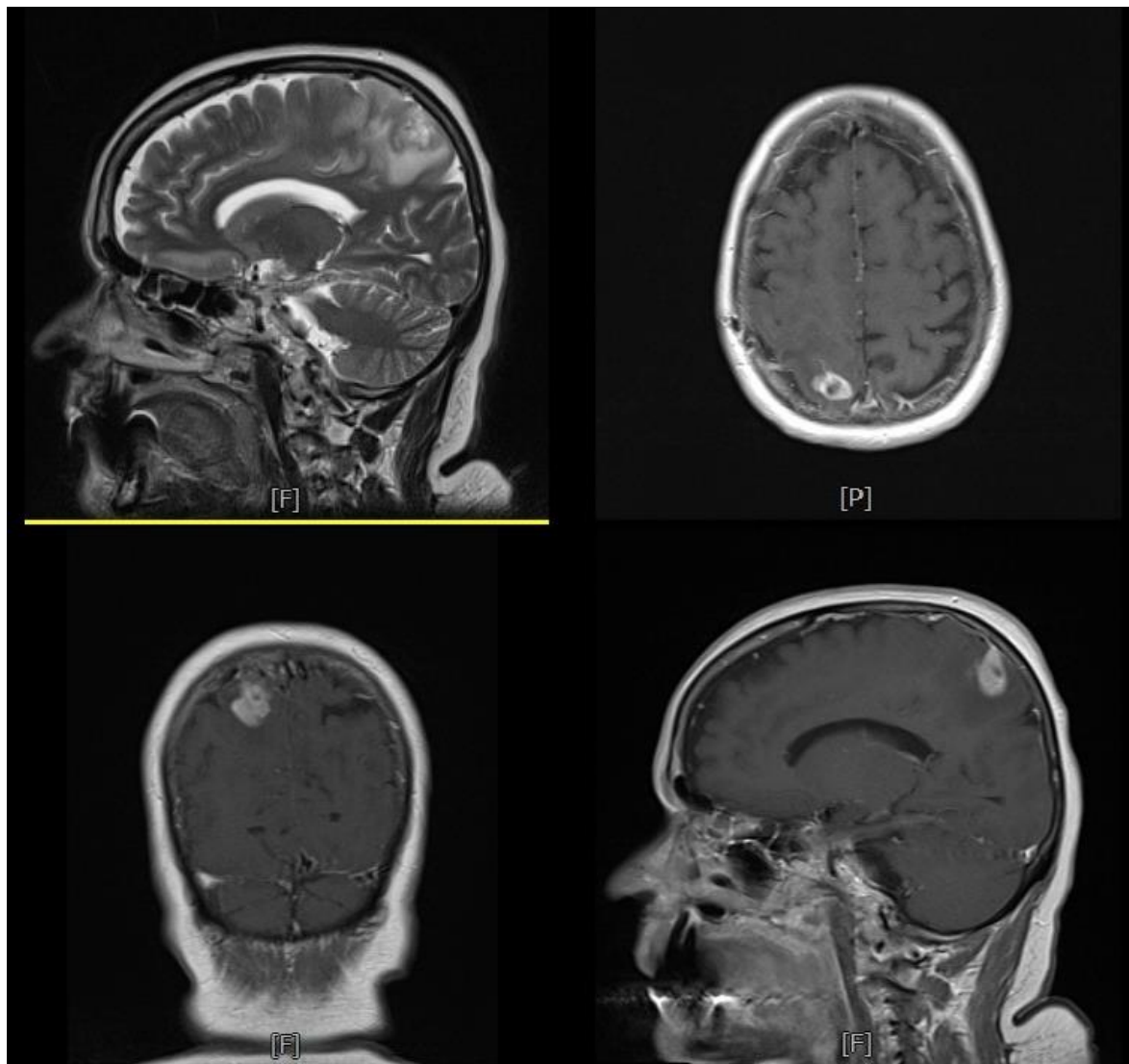
cellular telephones, radiofrequency exposures; and some infectious agents or immunologic responses and chromosomal mutations have also been studied for other types of gliomas (4).

Diagnosis

The signs and symptoms of primary brain tumors can vary widely, primarily depending on factors such as the tumor's location within the brain, the presence or absence of increased intracranial pressure, the tumor's size, and the extent of surrounding edema (3). These clinical manifestations encompass headaches, papilledema, vomiting,

cranial nerve involvement, ataxia, hearing and visual problems, personality changes, paresis/hypoesthesia, acute intracranial hypertension, focal neurological alterations, altered mental status, and gait dysfunction. High-grade gliomas may also manifest as speech arrest, seizures, and isolated peripheral facial paresis (1,3,7). Patients with GBM often report a timeline that ranges between 3-6 months for symptom progression. In the case of secondary GBM, this timeline can span over several years. Notably, individuals with rapidly progressing symptoms may initially be misdiagnosed with a stroke (3).

Figure 1. An original Magnetic resonance imaging, from our patient's database, shows hyperintensity in the parietal lobe that is compatible with glioblastoma



While clinical manifestations are frequent, diagnostic imaging studies, including computed tomography (CT) and magnetic resonance imaging (MRI), are often required to visualize the tumor and its characteristics. In select cases, an 18-fluoroethyltyrosine positron emission tomography (PET) scan may be employed for further evaluation (1,3,7).

Treatment

Some studies review different approaches and possible targeting therapies, but curative therapy has not been described. Current treatments and therapies are focused on symptomatic improvement and quality of life. Glucocorticosteroids treat symptoms, while radiotherapy and chemotherapy are the core therapeutic modalities. Several surgical modalities are involved in high-grade glioma management, such as biopsy, which seeks to achieve a histological diagnosis with minimal risk, and further therapy can be used. The resection objective is to remove the majority of the tumoral mass, leading to symptomatic relief and increased survival. Treatments and interventions are classified as (1):

Biopsy

One of the minimally invasive procedures is the biopsy where the main objective is obtaining a tumor sample (1). Omuro *et al.*, compared the overall survival between the total gross resection with partial resection or biopsy, finding that patients who underwent total gross resection had a median overall survival of 26 months, vs 16 months in the second group (8). Biopsy has also been used as part of the algorithm to diagnose recurrent high-grade gliomas; later, CyberKnife was used (9).

Resection

As part of the surgical treatment options, the extended resection thresholds following 78%-98% increase the survival. This extended resection is achieved with 5-aminolevulinic acid since it helps to identify and differentiate high-grade glioma from normal brain tissue due to its fluorescent effect when observed under blue light via a

microscopic light source. Despite this advantage, the blue light effect depends on the distance between the light and the tumor; therefore, endoscopic blue light might be seen as an alternative to advance the light source directly into the resection cavity (10).

An alternative to treating glioblastoma multiforme using 5-aminolevulinic acid is the use of a 3-dimensional digital exoscope. This alternative allows enhanced visualization of fluorescence and brain tissue under blue-light conditions. When conventional microscopes are used, the user directly visualizes the light reflected from the surgical field. On the other hand, the exoscope captures the reflected light using video chip technology, and the images are processed and projected via a proprietary, optimized data transfer link on high-resolution monitors. This technology can capture images even in very low-light conditions; therefore, fluorescence and normal brain tissue can be visualized. In a study conducted by Michael A. Vogelbaum *et al.*, 121 specimens were obtained, and authors classified the samples as strong fluorescence (40 specimens), weak fluorescence (40 specimens), and no fluorescence (41 specimens). The histopathological evaluation showed abundant tumor cells in 82.5% of the strong fluorescence group, while 17.5% showed scarce tumor cells; however, all strong fluorescence samples had neoplastic cells. On the other hand, the weak fluorescence group showed abundant tumor cells in 72.5% of the samples, while 17.5% showed scarce, and 10% showed none. In the non-fluorescence group, 34.2% showed abundant tumor cells, 26.8% showed scarce, and 39% showed none. The sensitivity was 75%, and specificity 80%, while the positive predictive value was 95% and the negative predictive value 39%. Strong fluorescence specimens predicted the presence of neoplasm, while weak fluorescence specimens suggested the highly infiltrative nature of high-grade glioma (11).

In the case of brainstem gliomas, surgical procedures have a major risk in a highly eloquent area, making it difficult to achieve high-quality evidence concerning the risk/benefit ratio of surgery as well as of post-surgical treatments. In the last 15 years, diagnostic and prognostic tools such as

molecular markers, the recent identification of H3 K327M mutation in midline gliomas with a low rate of MGMT promoter methylation, are related to improved surgical/intraoperative monitoring techniques, and the identification of safe entry zones, helping to optimize an extended resection, as well as an improved patient's survival (7).

Surgical intervention can be followed by radiotherapy to eliminate residual tumor cells; a strategy that has been demonstrated to extend the life expectancy of individuals with high-grade gliomas. Brachytherapy and stereotactic radiosurgery have shown effectiveness against recurrent GBM, although their roles in treating newly diagnosed GBM remain unclear, and hypofractionated radiotherapy has been associated with unfavorable survival outcomes in certain subgroups of patients (3). In the realm of neurooncology and surgical practice, the management of high-grade gliomas, notably glioblastoma, remains a formidable challenge. The current gold standard of care for stage IV gliomas involves maximal surgical resection, subsequent radiotherapy, and Temozolomide chemotherapy (12,13).

Gamma Knife Stereotactic Radiosurgery

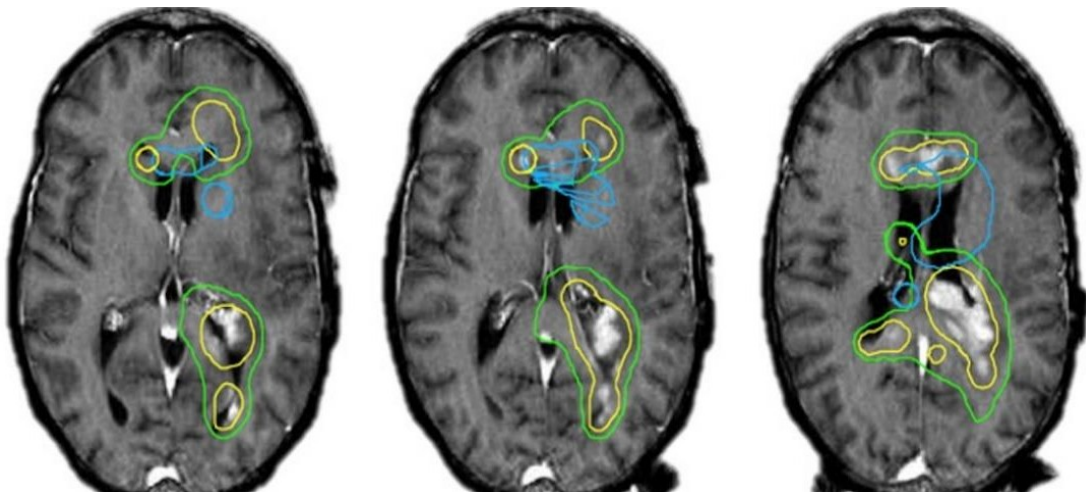
A significant development in the treatment landscape is Gamma Knife Stereotactic Radiosurgery (GKRS), which has emerged as a key therapeutic

option for a range of central nervous systems (CNS) lesions, whether benign or malignant. GKRS provides a noninvasive and comparatively safe approach, delivering swift results (14). This procedure employs the precise alignment of multiple ionizing beams to deliver low-energy radiation to a precisely defined target area, leading to focused tissue destruction (15,16). Notably, it induces endothelial apoptosis while causing minimal harm to the surrounding healthy brain tissue, making it an appealing choice for treating brain tumors (16,17). Although, radiation necrosis and peripheral hemorrhage have been considered potential side effects of GKRS, its effectiveness in treating glioblastoma, despite its infiltrative nature and unclear margins, has been substantiated (18–20).

Possible future treatment alternatives

Several chemotherapeutic agents have been explored to enhance patient survival in GBM treatment. Alkylating agents such as temozolomide (TMZ), carmustine (BCNU), and lomustine (CCNU) have demonstrated some benefits and are widely used in clinical practice. However, BCNU and CCNU, while effective, are associated with the early development of resistance and various side effects. TMZ is the standard chemotherapy for GBM patients, with its principal mechanism involving DNA methylation at guanine positions,

Figure 2. An original Magnetic resonance imaging, from our patient's database, for brain stereotactic radiosurgery planning



leading to DNA repair system failure, cell cycle arrest, and apoptosis. High Methyl Guanine Methyl Transferase (MGMT) activity in tumor cells is associated with poor TMZ response, and TMZ itself induces side effects. In addition to conventional therapies, emerging radiation-based treatments like intensity-modulated radiation therapy and boron neutron capture therapy are being explored for malignant glioma patients. These approaches offer reduced toxicity and decreased exposure to healthy tissues compared to standard radiotherapy (3).

A phase II study conducted by Megan Mantica et al. assessed the efficacy of border zone stereotactic radiosurgery with bevacizumab in patients with recurrent glioblastoma. Even though, overall survival did not improve, they showed the feasibility and tolerability of the combination of border zone stereotactic radiosurgery with bevacizumab (21). On the other hand, bevacizumab use has also been compared between radiotherapy and reradiation therapy + bevacizumab by Daniel P. Kulinich et al. in a systematic review, which suggested a potential benefit of reradiation therapy+ bevacizumab. However, they concluded that their findings were limited due to inconsistent data in reporting and heterogeneity in study methodologies. They also concluded that their systematic review findings supported the need to develop more randomized prospective studies to evaluate the potential benefit of bevacizumab in patients with gliomas (22).

These future studies should clarify the optimal protocols for using reradiation therapy and bevacizumab regimens.

Acknowledgments

We would like to express our sincere gratitude to the Latinoamerica Valerio Foundation for their invaluable support in advancing neuroscience research.

Conflict of interest statement

The authors declare that the research was conducted in the absence of any commercial or financial relationships that could be construed as a potential conflict of interest.

References

1. Hart MG, Grant GRL, Solyom EF, Grant R. Biopsy versus resection for high-grade glioma. Vol. 2019, Cochrane Database of Systematic Reviews. John Wiley and Sons Ltd; 2019.
2. Perlow HK, Prasad RN, Yang M, Klamer B, Matsui J, Marrazzo L, et al. Accelerated hypofractionated radiation for elderly or frail patients with a newly diagnosed glioblastoma: A pooled analysis of patient-level data from 4 prospective trials. *Cancer*. 2022 Jun 15;128(12):2367–74.
3. Hanif F, Muzaffar K, Perveen K, Malhi SM, Simjee SU. Glioblastoma Multiforme: A Review of its Epidemiology and Pathogenesis through Clinical Presentation and Treatment. *Asian Pac J Cancer Prev*. 2017 Jan 1;18(1):3–9.
4. Wrensch M, Minn Y, Chew T, Bondy M, Berger MS. Epidemiology of primary brain tumors: current concepts and review of the literature. *Neuro Oncol*. 2002 Oct;4(4):278–99.
5. National Cancer Institute. Glioblastoma Multiforme Study.
6. Batchelor T, Shih HA. Management of glioblastoma in older adults. *UpToDate*. 2023 Aug 15;
7. Rigamonti A, Simonetti G, Silvani A, Rudà R, Franchino F, Villani V, et al. Adult brainstem glioma: a multicentre retrospective analysis of 47 Italian patients. *Neurological Sciences*. 2021 May 1;42(5):1879–86.
8. Omuro A, Beal K, Gutin P, Karimi S, Correa DD, Kaley TJ, et al. Phase II study of bevacizumab, temozolomide, and hypofractionated stereotactic radiotherapy for newly diagnosed glioblastoma. *Clinical Cancer Research*. 2014 Oct 1;20(19):5023–31.
9. Guan Y, Xiong J, Pan M, Shi W, Li J, Zhu H, et al. Safety and efficacy of Hypofractionated stereotactic radiosurgery for high-grade Gliomas at first recurrence: a single-center experience. *BMC Cancer*. 2021 Dec 5;21(1):123.
10. Strickland BA, Zada G. 5-ALA Enhanced Fluorescence-Guided Microscopic to Endoscopic Resection of Deep Frontal Subcortical Glioblastoma Multiforme. *World Neurosurg*. 2021 Apr 1;148:65.
11. Vogelbaum MA, Kroll D, Etame A, Tran N, Liu J, Ford A, et al. A Prospective Validation Study of the First 3D Digital Exoscope for Visualization of 5-ALA-Induced Fluorescence in High-Grade Gliomas. *World Neurosurg*. 2021 May 1;149:e498–503.
12. Waqar M, Roncaroli F, Djoukhadar I, Akkari L, O’Leary C, Hewitt L, et al. Study protocol: PreOperative Brain Irradiation in Glioblastoma (POBIG)

- A phase I trial. *Clin Transl Radiat Oncol*. 2023 Mar;39:100585.
13. Omuro A, DeAngelis LM. Glioblastoma and other malignant gliomas: a clinical review. *JAMA*. 2013 Nov 6;310(17):1842–50.
 14. Amelio D, Amichetti M. Radiation therapy for the treatment of recurrent glioblastoma: an overview. *Cancers (Basel)*. 2012 Mar 7;4(1):257–80.
 15. Lehrer EJ, Ruiz-Garcia H, Nehlsen AD, Sindhu KK, Estrada RS, Borst GR, et al. Preoperative Stereotactic Radiosurgery for Glioblastoma. *Biology (Basel)*. 2022 Jan 26;11(2):194.
 16. Sulman EP, Ismaila N, Armstrong TS, Tsien C, Batchelor TT, Cloughesy T, et al. Radiation Therapy for Glioblastoma: American Society of Clinical Oncology Clinical Practice Guideline Endorsement of the American Society for Radiation Oncology Guideline. *J Clin Oncol*. 2017 Jan 20;35(3):361–9.
 17. Chargari C, Magne N, Guy JB, Rancoule C, Levy A, Goodman KA, et al. Optimize and refine therapeutic index in radiation therapy: Overview of a century. *Cancer Treat Rev*. 2016 Apr;45:58–67.
 18. Waqar M, Trifiletti DM, McBain C, O'Connor J, Coope DJ, Akkari L, et al. Early Therapeutic Interventions for Newly Diagnosed Glioblastoma: Rationale and Review of the Literature. *Curr Oncol Rep*. 2022 Mar;24(3):311–24.
 19. Clarke J, Neil E, Terziev R, Gutin P, Barani I, Kaley T, et al. Multicenter, Phase 1, Dose Escalation Study of Hypofractionated Stereotactic Radiation Therapy With Bevacizumab for Recurrent Glioblastoma and Anaplastic Astrocytoma. *Int J Radiat Oncol Biol Phys*. 2017 Nov 15;99(4):797–804.
 20. Minniti G, Niyazi M, Alongi F, Navarra P, Belka C. Current status and recent advances in reirradiation of glioblastoma. *Radiat Oncol*. 2021 Feb 18;16(1):36.
 21. Mantica M, Drappatz J, Lieberman F, Hadjipanayis CG, Lunsford LD, Niranjan A. Phase II study of border zone stereotactic radiosurgery with bevacizumab in patients with recurrent or progressive glioblastoma multiforme. *J Neurooncol*. 2023 Aug 1;164(1):179–90.
 22. Kulinich DP, Sheppard JP, Nguyen T, Kondajji AM, Unterberger A, Duong C, et al. Radiotherapy versus combination radiotherapy-bevacizumab for the treatment of recurrent high-grade glioma: a systematic review. Vol. 163, *Acta Neurochirurgica*. Springer; 2021. p. 1921–34.