







DOI: <https://doi.org/10.5554/22562087.e1116>

Ultrasound-guided neuraxial anesthesia versus the use of anatomical landmarks in the elderly: prospective cohort study

Anestesia neuroaxial guiada por ultrasonido vs. reparos anatómicos en ancianos: Estudio de cohorte prospectivo

Andrés Fabricio Caballero-Lozada^{a,c} , Genji Sakamoto-T^a , Diana Carreño-Medina^a , María Fernanda Pantoja^a , Fernando Velásquez^a , Andrés Velásquez^a ^aDepartment of Anesthesiology and Resuscitation. Universidad del Valle. Cali, Colombia.^bAnesthesiology Department, Hospital Universitario del Valle. Cali, Colombia.^cAnesthesiology Department. Fundación Hospital San José Buga. Buga, Colombia.**Correspondence:** Departamento de Anestesia y Reanimación, Universidad del Valle, Calle 13 # 100-00. Cali, Colombia.**E-mail:** andres.caballero@correounivalle.edu.co

What do we know about this problem?

· Spinal anesthesia guided by anatomical landmarks has been reported as inaccurate because it does not consider anatomical variants or acquired alterations. Additionally, there is a potential increase in the risk of spinal hematoma, post dural puncture headache and transient or permanent neurological deficit.

· As for the use of ultrasound to guide spinal anesthesia, it has been found to make the process easier, requiring less lumbar puncture attempts and improving pain scores and discomfort in elderly patients.

What is new from this study?

The results suggest that US-guided neuraxial anesthesia in the elderly is safe and could facilitate neuraxial block on first attempt.

How to cite this article:

Caballero-Lozada AF, Sakamoto-T G, Carreño-Medina D, Pantoja MF, Velásquez F, Velásquez A. Ultrasound-guided neuraxial anesthesia versus the use of anatomical landmarks in the elderly: prospective cohort study. Colombian Journal of Anesthesiology. 2024;52:e1116.

Abstract

Introduction: Spinal anesthesia requires palpation of surfaces in order to identify the intervertebral spaces in the lumbar spine. In elderly individuals, the procedure is more challenging due to age-related degenerative changes in the spine.

Objective: To determine which technique between ultrasound (US) guidance or the use of anatomical landmarks to guide spinal anesthesia ensures a higher success rate in elderly patients.

Methods: Prospective observational cohort study in patients with an indication to receive subarachnoid anesthesia, regardless of the type of surgical intervention, carried out at Hospital Universitario del Valle and Fundación Hospital San José Buga. Data were collected over a 12-month period at the time of making the puncture. The treating anesthetists were free to choose between US guidance or the use of anatomical landmarks.

Results: Overall, 80 patients were assessed, including men and women over 65 years of age (mean 78.50±9.04). The number of punctures as well as needle redirections were significantly lower in the US-guided group. Additionally, in the group in which anatomical landmarks were used to guide the puncture, the marked site did not coincide with the actual puncture site confirmed with US in 37.5% of cases ($p < 0.001$). This could result in inadequate block or complications associated with intradural puncture.

Conclusions: US-guided neuroaxial anesthesia in elderly individuals could facilitate success on the first attempt.

Keywords: Anesthesia; Spinal Puncture; Aged; Ultrasonography; Orthopedic Procedures; Anesthesiology.

Resumen

Introducción: La anestesia espinal se realiza mediante palpación de superficies para la identificación de los espacios intervertebrales lumbares. En adultos mayores el procedimiento presenta mayor dificultad debido a los cambios degenerativos de la columna vertebral asociados a la edad.

Objetivo: Evaluar cuál técnica de anestesia espinal garantiza una mayor tasa de éxito entre la guiada por ultrasonido (US) y la guiada por reparos anatómicos (RA) en adultos mayores.

Métodos: Estudio observacional de cohorte prospectivo en pacientes con indicación de suministro de anestesia subaracnoidea independientemente de la intervención quirúrgica, llevado a cabo en el Hospital Universitario del Valle y la Fundación Hospital San José Buga. En un lapso de 12 meses se recolectaron datos durante la realización de la punción, según decisión del anesthesiólogo tratante, guiada por US vs. RA.

Resultados: En total se evaluaron 80 pacientes entre hombres y mujeres, mayores de 65 años, con edad media de $78,50 \pm 9,04$. El número de punciones, así como de redireccionamientos, fue significativamente menor en el grupo guiado por US. Adicionalmente, se observó que en el grupo guiado por RA, el 37,5 % no coincidía con el sitio demarcado con el espacio real de punción confirmado con US ($p < 0,001$). Podría ser la causa de un bloqueo inadecuado o de complicaciones de la punción intradural.

Conclusiones: La técnica de anestesia neuroaxial guiada por US en adultos mayores podría facilitar el bloqueo neuroaxial al primer intento de punción.

Palabras clave: Anestesia; Punción espinal; Anciano; Ultrasonografía; Procedimientos ortopédicos; Anestesiología.

INTRODUCTION

Spinal, epidural and caudal neuraxial anesthesia provide a combination of sympathetic, sensory or motor block as a function of dose, concentration or volume of the local anesthetic, with a wide range of clinical applications in surgical procedures, acute postoperative pain treatment and chronic pain relief (1).

Traditionally, the spinal anesthesia technique is based on the use of anatomical landmarks for the identification of the interspinous space. These include the posterior midline, iliac crests and the line that connects them (Tuffier's line), generally associated with the vertebral body of L4 or the L4-L5 intervertebral space, and the spinous processes, although with very low concordance (2). The difficulty increases depending on the degree of expertise and the ability to identify anatomical surfaces by palpation, which can be limited in obese or elderly patients (1,3,4). Moreover, multiple puncture attempts may cause patient

discomfort and increase the risk of spinal hematoma, post dural puncture headache (PDPH) and neurologic deficit (5-7).

Recently, ultrasonography (US) has been used to identify landmarks before spinal anesthesia (8-10), as it allows to assess spinal anatomy and identify any abnormalities in this axial structure (11,12). It also enables localization of the most adequate intervertebral space for easy access with the spinal needle, and to identify the depth at which it should be inserted (13,14). Moreover, nerve roots and conus medullaris position can be localized in order to determine the safest access level with a higher probability of success (15). The aim is to reduce the number of attempted punctures and associated risks in patients with difficult access for spinal anesthesia (9,16,17).

Despite the safety profile of neuraxial anesthesia, risks and adverse effects still exist. The most common complications include PDPH, dural hematoma formation, lumbar pain and secondary spinal cord

injury, as well as low success rate (as low as 30%) with the adequate identification of the puncture level using anatomical landmarks (18). Risk factors for these types of complications have been divided into three groups: patient-related factors such as hemostatic or spinal disorders; procedure-related factors such as complicated spinal anesthesia, including the main risk of retrieving bloody cerebrospinal fluid; and drug-related factors such as the use of anticoagulants (19). According to Lagerkranser et al. (19), the risk of spinal hematoma is higher in patients over 60 years of age and more significantly so in women (19).

The introduction of US in neuraxial anesthesia has improved patient and clinical safety because of accurate identification of the adequate puncture site, the midline and the intervertebral space, with a higher rate of success on first attempt and a lower number of needle passes (18) — the latter having been described as a risk factor for PDPH, spinal hematoma and lumbar pain

(18,20). The aim of US guidance during spinal anesthesia (SA) is to visualize and measure the puncture site, thus avoiding multiple attempts, particularly in patients with a difficult anatomy (14,18). It is worth mentioning that, although the use of US could add time to the spinal anesthesia procedure, patients benefit from increased comfort and a higher probability of a successful puncture which, according to the literature, results in lower rates of associated lumbar pain (13,18).

US in spinal anesthesia is extremely useful, especially in older patients in whom age-related technical difficulties can be expected because of degenerative changes, interspinous ligament calcification or acquired spine deformities. Acquiring ultrasound images before spinal anesthesia through the median and paramedian approaches in older patients undergoing orthopedic surgery reduces the number of punctures, making the procedure easier and improving pain scores and patient discomfort (21,22). Against this background, the purpose of this study was to determine which spinal anesthesia technique (US vs. anatomical landmark guidance) results in higher success rates in the elderly. The secondary objectives were to identify and document complications arising during US or anatomical landmark-guided anesthesia, as well as the number of puncture attempts needed to achieve successful spinal anesthesia.

METHODS

Study design and participants

Prospective observational study of patients over 65 years of age scheduled for elective or urgent surgery under spinal anesthesia admitted between October 2021 and November 2022 to Hospital Universitario del Valle, a level III institution, and Fundación Hospital San José Buga. Convenience sampling was used. The study was approved by the ethics committee of Hospital Universitario del Valle with record

number 011-2021. The inclusion criteria were patients undergoing orthopedic surgery, umbilical and inguinal hernia repair, open or transurethral prostatectomy, pelvic floor surgery, older than 65 years of age and American Society of Anesthesia classification I - III, with optimal cognitive ability to collaborate with positioning and who had signed the informed consent to undergo the technique and participate in the study.

Exclusion criteria were with at least one of the following: patients with contraindication for subarachnoid anesthesia, a history of lumbar surgery, a history of allergic reaction to local anesthetics, or refusal to participate.

Patients were assigned in alternating order to one of the two groups as they came (one group with subarachnoid anesthesia guided by anatomical landmarks and a second group with US guidance). The median and paramedian approaches were used, depending on the choice of the anesthetist performing the procedure. The choice of guidance was also left to the anesthetist. This article is reported in accordance with the STROBE tool.

Standard procedure

In all patients, the procedure was performed after obtaining the informed consent, and establishing peripheral venous access and basic monitoring as recommended by ASA, using pulse oximetry, electrocardiography and non-invasive blood pressure monitoring. Moreover, all usual asepsis and antisepsis measures were implemented, and the ultrasound probe was wrapped in sterile material. The procedure was performed by two anesthetists experienced in both US and anatomical landmark-guided anesthesia who were not involved in the study. Their experience having performed at least 50 US-guided procedures was confirmed. For both groups, the approach was based on mapping, assessing the best puncture space and defining which space was being measured.

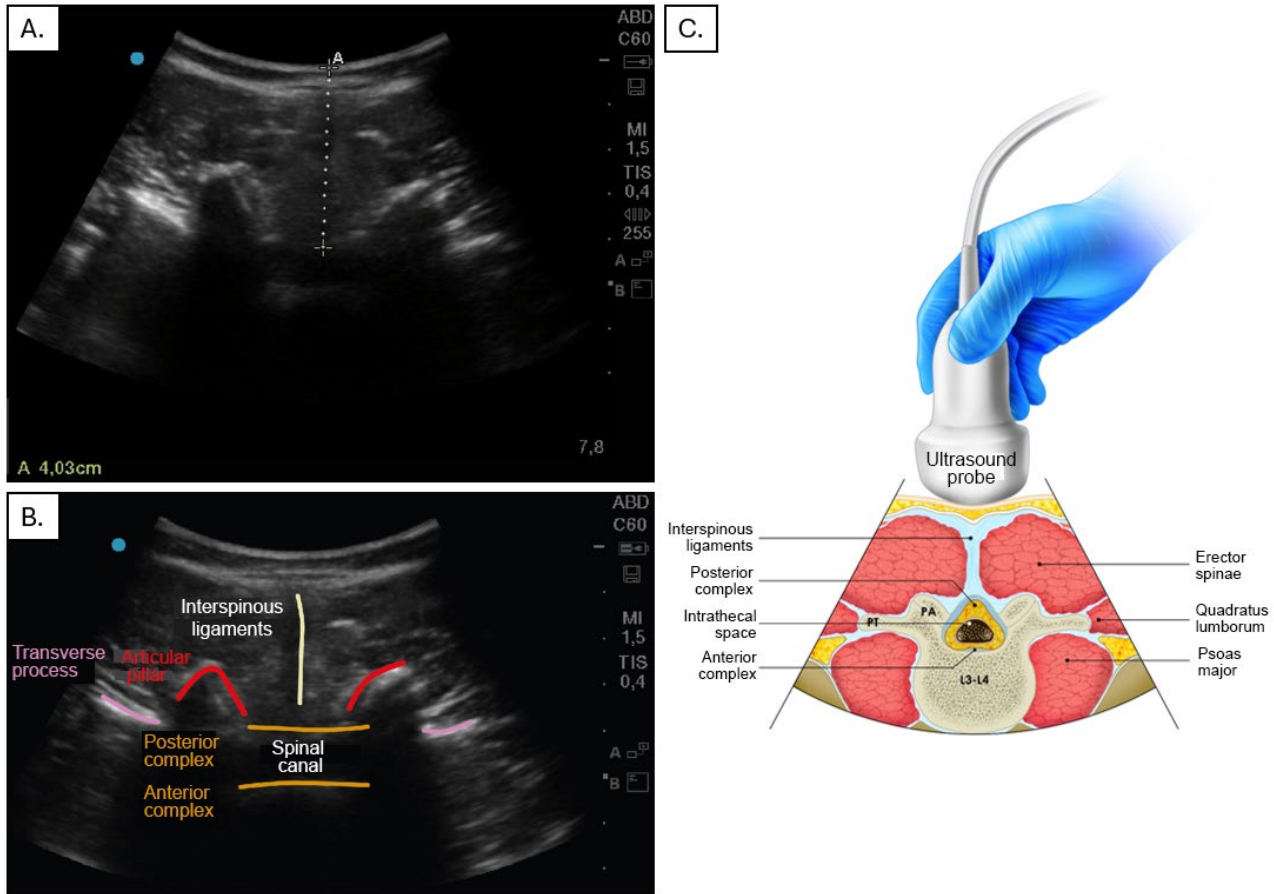
In the US-guided group the steps included equipment preparation (Sonosite M Turbo machine), patient positioning, identification of the spinous processes and placement of the convex ultrasound probe (2-5 MHz) initially on the sacrum on a longitudinal plane at the level of the laminae, identification of the intervertebral space, and selection of the puncture site based on the widest exposed space. A transverse view was acquired of the intervertebral space, taking into account the best probe angulation to visualize the space and measure the distance between the skin and the subarachnoid space (Figure 1). Finally, spaces and puncture site were marked and the puncture made with a Quincke # 26 or 27 needle (Figure 2).

In the group with anatomical landmark guidance, the US equipment was prepared with the low frequency transducer after positioning the patient in sitting or lateral decubitus position — according to the preference of the treating anesthetist. The midline was then identified by means of palpation of the spinous processes and intervertebral spaces; the L4-L5 space location was estimated by drawing an imaginary line between the iliac crests (Tuffier's line) (2). Once the right space was localized, a Quincke 26 or 27 gauge needle was used to perform the puncture (Figure 3). Local anesthetic was administered and the puncture site was confirmed with ultrasound, outlining the intervertebral spaces from the sacrum up to the puncture site.

Data collection

The variables of interest measured were collected by the anesthetist in charge of performing the puncture and by the licensed practical nurse who were aware of the study and its purpose, and using a stop watch available in the operating room. The following variables were taken into consideration: lumbar puncture site, US confirmation of the site, number of punctures, number of redirections, time in minutes needed to establish anesthesia — from the moment anatomical landmarks

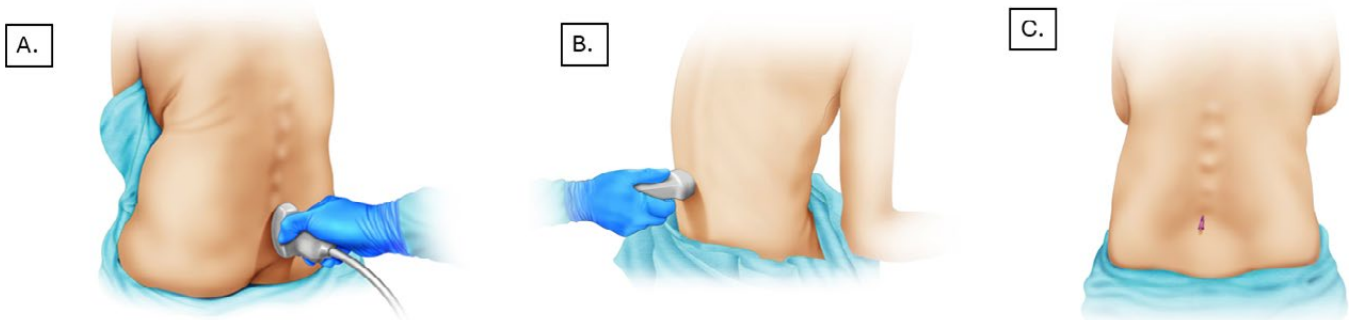
Figure 1. US-guided anesthesia.



A. Transverse view of the lumbar spine, with the dotted line representing the distance between the skin and the subarachnoid space. B and C. Transverse view showing the various structures along this plane: interspinous ligaments, transverse process, posterior and anterior complex, and spinal canal.

Source: Authors.

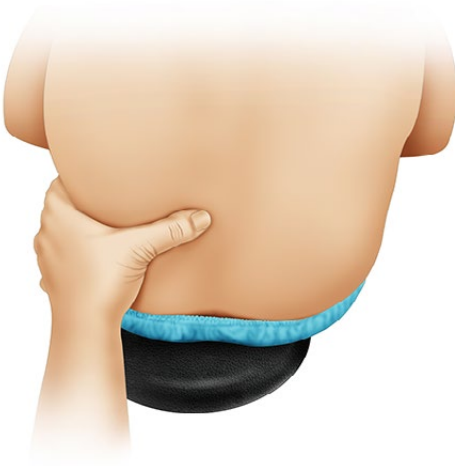Figure 2. US-guided anesthesia.



A. The probe is initially placed at the level of the sacrum with a caudal-cranial orientation for better space localization. B. Identification and measurement of structures in the transverse plane. C. Lumbar puncture taking into account distance and scanning angle.

Source: Authors.

Figure 3. Anatomical landmarks. Midline determination based on palpation of the spinous processes and puncture level according to Tuffier's line.



Source: Authors.

were ascertained to the intrathecal administration of the local anesthetic — and puncture landmarks.

Statistical analysis

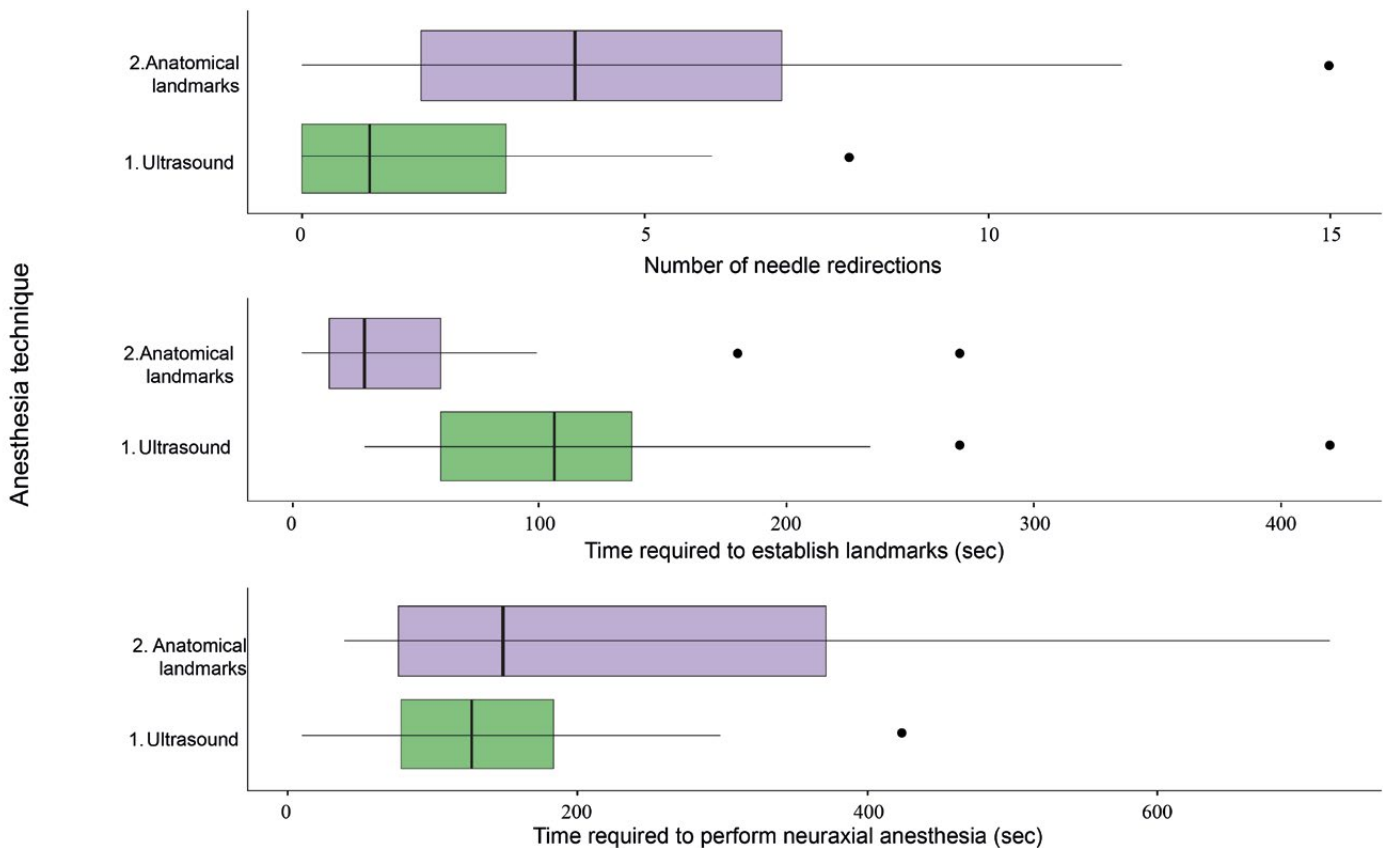
A descriptive analysis of the data was performed, making a distinction according to the anesthesia technique used (US group and anatomical landmark group) and number of puncture attempts (one or more than one). Quantitative variables were presented as mean and standard deviation, or median and interquartile range (IQR), depending on whether the normality assumption was met or not. Qualitative variables were presented in frequency and proportion tables. The chi-square test or the Fisher's exact test was used when

both variables were categorical, and the Mann-Whitney U test or the Student t test was used for comparing categorical and quantitative variables.

The time required to perform the anesthesia procedure as well as the number of needle redirections were also assessed. Since outcome variables were quantitative, central trend measurements were used, considering a statistical significance level equal to 0.05 or lower. The variables that were considered relevant in the descriptive analysis were later used to build box and whisker plots.

Finally, relative risk (RR) for sex, age, anesthesia technique, body mass index (BMI) and position at the time of performing the anesthesia was estimated, with success being defined as puncture on first attempt. Additionally, a binary response model was adjusted in order to estimate RR.

Figure 4. Time and number of redirections.



Source: Authors.

RESULTS

The study included 80 patients with a mean age of 78.50±9.04 (50 women and 30 men), with associated comorbidities such as diabetes mellitus (25%), hypertension (58%), and chronic kidney disease (11%) ([Complementary material 1](#)).

In terms of puncture numbers, success in achieving spinal anesthesia on first attempt was higher in the US group (US 72.5% vs. anatomical landmark group 45.0%; $p=0.02$). The number of needle redirections was also lower in the US group (US group median = 1; landmark group = 4); the time taken to localize the puncture site was longer in the US group, but the total mean time to achieve anesthesia, measured from the time of landmark establishment to the administration of the drug, was 137 (78.25-243.75) with no difference between the two groups ([Figure 4](#)).

Patients were positioned either on lateral decubitus or in sitting position depending on the preference of the treating anesthetist, with the sitting position being used more frequently in the US group (75% vs. 42% $p=0.01$) ([Table 1](#)).

No complications such as spinal hematoma, lumbar pain or PDPH were observed or reported in either group. Additionally, RR was estimated by sex, age, anesthetic technique, BMI and position at the time of puncture. A level of statistical significance was found for success on first attempt with US and for the sitting position ([Table 2](#)). A binary response model adjustment was used to estimate adjusted RR.

In the anatomical landmark group, puncture site confirmation was made after spinal anesthesia placement, and inconsistency with the previously estimated site was found in 37.5% of patients. This creates the risk of not being able to achieve anesthetic block in the adequate site.

DISCUSSION

The results of this study showed that the use of ultrasound for neuraxial anesthesia in elderly patients is extremely helpful

Table 1. Variable analysis by groups.

Clinic characteristics				
Variable	US Group n (%)	Landmark group n (%)	Total n (%)	Valor p
Lumbar puncture site	n = 40	n = 40	n = 80	0.41
SL_L2-L3	10(25.00)	12(30.00)	22(27.50)	
SL_L3-L4	28(70.00)	23(57.50)	51(63.75)	
SL_L4-L5	2(5.00)	5(12.50)	7(8.75)	
Lumbar puncture site confirmation	n = 40	n = 40	n = 80	0.05
SL_L1-L2	0(0.00)	1(2.50)	1(2.50)	
SL_L2-L3	11(27.50)	20(50.00)	31(38.75)	
SL_L3-L4	27(67.50)	26(40.00)	43(53.75)	
SL_L4-L5	2(5.00)	3(7.50)	5(6.25)	
Number of lumbar puncture attempts	n = 40	n = 40	n = 80	0.02
One	29(72.50)	18(45.00)	47(58.75)	
More than one	11(27.50)	22(55.00)	33(41.25)	
Number of needle redirections	n = 40	n = 40	n = 80	0
Median (IQR)	1(0-3)	4(1.75-7)	2(1-5)	
Number of Gn needle redirections	n = 40	n = 40	n = 80	0
0 to 1	24(60.00)	10(25.00)	34(42.50)	
Between 2 and 6	15(37.50)	19(47.50)	34(42.50)	
Between 7 and 9	1(2.50)	6(15.00)	7(8.75)	
More than 9	0(0.00)	5(12.50)	5(6.25)	
Time required to establish anatomical landmarks	n = 40	n = 40	n = 80	0
Median (IQR) sec	106.5(60-138)	30(15-60)	60(30-120)	
Time required to perform anesthesia	n = 40	n = 40	n = 80	0.15
Median (IQR) sec	128(78.25-184.25)	150(77-372)	137(78.25-243.75)	
Position at the time of anesthesia	n = 40	n = 40	n = 80	0.01
Right lateral decubitus	10(25.00)	23(57.50)	33(41.25)	
Sitting	30(75.00)	17(42.50)	47(58.75)	
Total (n)	n = 40	n = 40	n = 80	
Puncture depth	5.15(4.92-6.05)	5.85(5-6.58)	5.35(5-6.5)	0.36

IQR: Interquartile range; Sec: Seconds; US: Ultrasound.

Source: Authors.

and could be associated with a higher rate of success of spinal anesthesia on first attempt.

The geriatric population is growing worldwide and these are patients who usually present with multiple medical comorbidities and underlying bone fragility because of loss of bone mineral density and muscle mass, creating a higher risk for perioperative and postoperative complications ([23](#)). Patient age has been

found to be an independent predictor of increased technical difficulty with neuraxial anesthesia as a result of degenerative changes affecting the neural axis ([24](#)). Narrowing of interspinous and intervertebral spaces can be found in elderly patients due to interspinous ligament ossification and facet joint hypertrophy ([25,26](#)). This difficulty identifying the interspinous space is compounded by the difficulty in achieving adequate lumbar flexion,

Table 2. Risk estimation at the time of puncture considering success as puncture on first attempt.

Variable	OR estimations		
	Crude RR (95% CI)	Adjusted RR (95% CI)	p value
Age	1.1(0.76-1.61)	1.02 (0.97-1.08)	0.47
Sex	0.97(0.66-1.41)	1.98(0.66-6.45)	0.24
Anesthesia technique: US	0.62(0.42-0.92)	0.35(0.11-0.99)	0.05
Body mass index	0.93(0.64-1.34)	1(0.88-1.13)	0.96
Position: Sitting	0.54(0.34-0.86)	0.28(0.09-0.79)	0.02

Source: Authors.

limiting adequate patient position for the administration of spinal anesthesia (27-29).

Although additional time is usually required for finding anatomical landmarks with the use of US, when total time for spinal anesthesia is analyzed, it appears that there are no differences when compared with the use of anatomical landmarks to guide the technique. This is probably due to the higher number of punctures and needle redirections needed with the latter.

The use of ultrasound to approach the neural axis has been described both in the context of acquiring images before the spinal anesthesia procedure and site marking, as well as in real-time needle guidance, with the majority of studies conducted in the obstetric population. However, we present results in elderly patients that support the use of US as a safe and effective alternative to guide spinal anesthesia. It is important to highlight that, unlike the anatomical landmarks group, the sitting position was the predominant position in the US group.

This observational study has limitations, including the absence of standardized surgical indications or associated comorbidities which could make positioning more challenging. Sample size was small and, because of its design, the study was not randomized or blinded. Data were collected in two hospitals, limiting generalization of the findings; moreover, potential selection bias could have been induced because anesthetists could have chosen US in those patients with additional predictors of difficult lumbar approach besides age. There were

no major complications associated with the procedure. A cost-effectiveness analysis comparing the US-guided technique vs. the technique based on anatomical landmarks was not performed; however, ultrasound machines were available in both institutions, so no procurement costs were involved. Randomized controlled studies with larger sample sizes are required in order to confirm the superiority of ultrasound guidance when compared with the use of anatomical landmarks to guide spinal anesthesia.

CONCLUSION

The use of ultrasound guidance for procedures such as spinal anesthesia in elderly patients is an option that could improve success on first puncture, with no significant impact on the time required to achieve final anesthesia. However, due to the limitations of this study, it is important to conduct additional, more robust research with larger sample sizes like a randomized study, in order to validate these results.

ETHICAL RESPONSIBILITIES

Ethics committee approval

This study was approved by the ethics committee of Hospital Universitario del Valle, as set forth in Minutes 011-2021 of the 21st of March, 2021, in Cali, Colombia.

Protection of human and animal subjects

The authors declare that no experiments were performed on humans or animals for this study.

Confidentiality of data

The authors declare that they have followed the protocols of their work center on the publication of patient data.

Right to privacy and informed consent

The authors declare that no patient data are disclosed in this article. Informed consent was obtained from all the participants.

ACKNOWLEDGEMENTS

Contributions by the authors

ACL, GST, DCM, MP, FV y AV: Substantial contributions to conception, study design, data collection and interpretation. All the authors contributed to the writing and critical review of the manuscript and approved the final version submitted to the journal.

Assistance for the study

None declared.

Conflicts of interest

The authors have no disclosures to make.

Funding

None declared.

Presentations

This manuscript was presented as poster/lecture in the following events:

-Poster: XXXV Colombian Congress of Anesthesiology and Resuscitation in July 2023 and was awarded first place in the poster category.

-Lecture: XXV National and International Health Research Symposium, in June 2023.

Appreciations

None declared.

REFERENCES

- Miller RD, Eriksson LI, Fleisher LA, Wiener-Kronish J, Cohen NH. Miller. Anesthesia (8a. ed.). Elsevier Inc.; 2015.
- Chun EH, Kim JE, Kim DY, Kim YJ, Kim JH, Chung RK, et al. Ultrasound measurement of the vertebral level of Tuffier's line in elderly women. *Korean J Anesthesiol.* 2016;69(5):474-9. <https://doi.org/10.4097/kjae.2016.69.5.474>
- Tanaka K, Irikoma S, Kokubo S. Identification of the lumbar interspinous spaces by palpation and verified by X-rays. *Braz J Anesthesiol.* 2013;63(3):245-8. [https://doi.org/10.1016/S0034-7094\(13\)70224-1](https://doi.org/10.1016/S0034-7094(13)70224-1)
- Broadbent CR, Maxwell WB, Ferrie R, Wilson DJ, Gawne-Cain M, Russell R. Ability of anaesthetists to identify a marked lumbar interspace. *Anaesthesia.* 2000;55(11):1122-6. <https://doi.org/10.1046/j.1365-2044.2000.01547-4.x>
- Davoudi M, Tarbiat M, Ebadian MR, Hajian P. Effect of position during spinal anesthesia on postdural puncture headache after cesarean section: A prospective, single-blind randomized clinical trial. *Anesth Pain Med.* 2016;6(4):e35486. <https://doi.org/10.5812/aapm.35486>
- Majd SA, Pourfarzam S, Ghasemi H, Yarmohammadi ME, Davati A, Jaberian M. Evaluation of pre lumbar puncture position on post lumbar puncture headache. *J Res Med Sci.* 2011;16(3):282-6.
- Kreppel D, Antoniadis G, Seeling W. Spinal hematoma: a literature survey with meta-analysis of 613 patients. *Neurosurg Rev.* 2003;26(1):1-49. <https://doi.org/10.1007/s10143-002-0224-y>
- Özdamar E, Özkaya AK, Güler E, Cantay B, Karabel N, Göksügür Y, et al. Ultrasound-assisted lumbar puncture in pediatric emergency department. *Pediatr Emerg Care.* 2017;33(8):e21-3. <https://doi.org/10.1097/PEC.0000000000000593>
- Nomura JT, Leech SJ, Shenbagamurthi S, Sierzynski PR, O'Connor RE, Bollinger M, et al. A randomized controlled trial of ultrasound-assisted lumbar puncture. *J Ultrasound Med.* 2007;26(10):1341-8. <https://doi.org/10.7863/jum.2007.26.10.1341>
- Du J, Roth C, Dontukurthy S, Tobias JD, Venezia G. Manual palpation versus ultrasound to identify the intervertebral space for spinal anesthesia in infants. *J Pain Res.* 2023;16:93-9. <https://doi.org/10.2147/JPR.S392438>
- Chin KJ, Perlas A, Chan V, Brown-Shreves D, Koshkin A, Vaishnav V. Ultrasound imaging facilitates spinal anesthesia in adults with difficult surface anatomic landmarks. *Anesthesiology.* 2011;115(1):94-101. <https://doi.org/10.1097/ALN.0b013e31821a8ad4>
- Gnaho A, Nguyen V, Villevielle T, Frota M, Mallet E, Gentili ME. Assessing the depth of the subarachnoid space by ultrasound. *Rev Bras Anesthesiol.* 2012;62(4):520-30. [https://doi.org/10.1016/S0034-7094\(12\)70150-2](https://doi.org/10.1016/S0034-7094(12)70150-2)
- Grau T, Leipold RW, Conradi R, Martin E, Motsch J. Efficacy of ultrasound imaging in obstetric epidural anesthesia. *J Clin Anesth.* 2002;14(3):169-75. [https://doi.org/10.1016/S0952-8180\(01\)00378-6](https://doi.org/10.1016/S0952-8180(01)00378-6)
- Chin KJ, Perlas A, Chan V. The ultrasound-assisted paraspinous approach to lumbar neuraxial blockade: a simplified technique in patients with difficult anatomy. *Acta Anaesthesiol Scand.* 2015;59(5):668-73. <https://doi.org/10.1111/aas.12502>
- Muthusami P, Robinson AJ, Shroff MM. Ultrasound guidance for difficult lumbar puncture in children: pearls and pitfalls. *Pediatr Radiol.* 2017;47(7):822-30. <https://doi.org/10.1007/s00247-017-3794-0>
- Shaikh F, Brzezinski J, Alexander S, Arzola C, Carvalho JC, Beyene J, et al. Ultrasound imaging for lumbar punctures and epidural catheterisations: systematic review and meta-analysis. *BMJ.* 2013;346:f1720. <https://doi.org/10.1136/bmj.f1720>
- Grau T, Leipold RW, Conradi R, Martin E, Motsch J. Ultrasound imaging facilitates localization of the epidural space during combined spinal and epidural anesthesia. *Reg Anesth Pain Med.* 2001;26(1):64-7. <https://doi.org/10.1053/rapm.2001.19633>
- Li J, Krishna R, Zhang Y, et al. Ultrasound-guided neuraxial anesthesia. *Curr Pain Headache Rep.* 2020;24:59. <https://doi.org/10.1007/s11916-020-00895-3>
- Lagerkranser M. Neuraxial blocks and spinal haematoma: Review of 166 case reports published 1994-2015. Part 1: Demographics and risk-factors. *Scandinavian J Pain.* 2017;15(1):118-29. <https://doi.org/10.1016/j.sjpain.2016.11.008>
- de Filho GR, Gomes HP, da Fonseca MH, Hoffman JC, Pederneiras SG, Garcia JH. Predictors of successful neuraxial block: a prospective study. *Eur J Anaesthesiol.* 2002;19(6):447-51.
- Park SK, Bae J, Yoo S, Kim WH, Lim YJ, Bahk JH, et al. Ultrasound-assisted versus landmark-guided spinal anesthesia in patients with abnormal spinal anatomy: a randomized controlled trial. *Anesth Analg.* 2020;130(3):787-95. <https://doi.org/10.1213/ANE.0000000000004600>
- Narkhede HH, Kane D, Parekh V, Hemanthkumar I. A cohort study of anatomical landmark-guided midline versus pre-procedure ultrasound-guided midline technique of spinal anesthesia in elderly patients undergoing orthopedic surgery. *J Anaesthesiol Clin Pharmacol.* 2019;35(4):522-7. https://doi.org/10.4103/joacp.JOACP_396_17
- Dawson J, Doll H, Boller I, Fitzpatrick R, Little C, Rees J, et al. Comparative responsiveness and minimal change for the Oxford Elbow Score following surgery. *Qual Life Res.* 2008;17(10):1257-67. <https://doi.org/10.1007/s11136-008-9409-3>
- Tessler MJ, Kardash K, Kleiman S, Rossignol M. A retrospective comparison of spinal and general anesthesia for vaginal hysterectomy: a time analysis. *Anesth Analg.* 1995;81(4):694-6. <https://doi.org/10.1097/0000539-199510000-00006>
- Huang F, Li H, Liu S, Zong M, Wang Y. Dual- vs. single-plane ultrasonic scan-assisted positioning during lumbar spinal puncture in elderly patients: a randomized controlled

- trial. *J Clin Med.* 2022;11(18):5337. <https://doi.org/10.3390/jcm11185337>
26. Darrieutort-Laffite C, Bart G, Planche L, Glemarec J, Maugars Y, Le Goff B. Usefulness of a pre-procedure ultrasound scanning of the lumbar spine before epidural injection in patients with a presumed difficult puncture: A randomized controlled trial. *Joint Bone Spine.* 2015;82(5):356-61. <https://doi.org/10.1016/j.jbspin.2015.02.001>
27. Uyel Y, Kilicaslan A. Preprocedural ultrasonography versus landmark-guided spinal anesthesia in geriatric patients with difficult anatomy: a prospective randomized trial. *Eurasian J Med.* 2021;53(1):9-14. <https://doi.org/10.5152/eurasianjmed.2020.20215>
28. Kim Y, Yoo S, Park SK, Bae H, Lim YJ, Kim JT. Optimal angle of needle insertion for spinal anesthesia in patients with spondylolisthesis: an ultrasonographic study. *BMC Anesthesiol.* 2021;21(1):221. <https://doi.org/10.1186/s12871-021-01444-0>
29. Srinivasan KK, Leo AM, Iohom G, Loughnane F, Lee PJ. Pre-procedure ultrasound-guided paramedian spinal anaesthesia at L5-S1: Is this better than landmark-guided midline approach? A randomised controlled trial. *Indian J Anaesth.* 2018;62(1):53-60. https://doi.org/10.4103/ija.IJA_448_17

COMPLEMENTARY MATERIAL

Complementary material 1. Sociodemographic categorization.

Clinical characteristics				
Variable	US group n (%)	Landmark group n (%)	Total n (%)	p value
Sex	n = 40	n = 40	n = 80	0.4
Female	20(50.00)	30(75.00)	50(62.50)	
Males	20(50.00)	10(25.00)	30(37.50)	
Age	n = 40	n = 40	n = 80	0.42
Mean (SD)	79.37(9.46)	77.72(8.65)	78.50(9.04)	
Age category	n = 40	n = 40	n = 80	0.5
60-79 years	20(50)	24(60)	44(55)	
80-99 years	20(50)	16(40)	36(45)	
Hypertension	n = 40	n = 39	n = 79	0.92
Yes	24(60.00)	22(55.00)	46(58.23)	
Diabetes mellitus	n = 40	n = 39	n = 79	1
Yes	10(25.00)	10(25.64)	20(25.32)	
Chronic kidney disease	n = 39	n = 39	n = 78	1
Yes	6(15.38)	5(12.82)	11(14.10)	
COPD	n = 40	n = 39	n = 79	0.61
Yes	3(7.50)	1(2.56)	4(5.06)	
Weight	n = 40	n = 40	n = 80	0.04
Median (IQR)	65(58.75-70.50)	61(54.00-66.00)	63(56.00-69.20)	
Height	n = 40	n = 40	n = 80	0.11
Mean (SD)	159.80(8.47)	157.10(6.56)	158.4(7.65)	
Group BMI	n = 40	n = 40	n = 80	0.5
Low-normal weight (17.25)	20(50.00)	24(60.00)	44(55.00)	
Overweight/obesity (25.37)	20(50.00)	16(40.00)	36(45.00)	
Consistent lumbar puncture site	n = 40	n = 40	n = 80	
Yes	40(100)	25(62.50)	65(81.25)	<0.001

BMI: Body Mass Index; COPD: Chronic obstructive pulmonary disease; IQR: Interquartile range; SD: Standard deviation; US: Ultrasound.

Source: Authors.